



# Amputation for histiocytic sarcoma in a cat

Journal of Feline Medicine and Surgery  
14(2) 147–150  
© ISFM and AAFP 2011  
Reprints and permission:  
sagepub.co.uk/journalsPermissions.nav  
DOI: 10.1177/1098612X11429226  
jfms.com



**Takahiro Teshima<sup>1</sup>, Takashi Hata<sup>2</sup>, Yoko Nezu<sup>2</sup>,  
Masaki Michishita<sup>3</sup>, Hirotaka Matsumoto<sup>1</sup>, Hisashi Mizutani<sup>1</sup>,  
Kimimasa Takahashi<sup>3</sup> and Hidekazu Koyama<sup>1</sup>**

## Abstract

A 9-year-old spayed female domestic shorthair cat presented with a skin lesion of the left tarsus. The lesion was biopsied and, based on the microscopic appearance and immunohistochemical characteristics, histiocytic sarcoma was diagnosed. Amputation was performed with improved demeanor seen postoperatively. However, between 44 and 60 days following the surgery, relapse of skin lesions appeared in multiple locations, including at the previous amputation site, and euthanasia was elected. This is the first report of a histiocytic sarcoma treated with amputation in a cat.

**Accepted:** 13 September 2011

A 9-year-old, 4.1 kg spayed female domestic shorthair cat presented to a private animal hospital with a complaint of a pyogenic and swollen skin lesion of the left tarsus of 10 days duration. On physical examination, the cat was alert, had a normal temperature (38.5°C) and body condition, tachycardia (222 bpm) with a III/VI systolic murmur, severe swelling and a solitary nodule on the left tarsus measuring 3 cm diameter at the widest point. Haematology revealed normal values for: packed cell volume 28.9% (reference interval (RI) 24.0–45.0%), haemoglobin: 9.2 g/dl (RI 8.0–15.0 g/dl), platelets 292,000/ $\mu$ l (RI 175,000–500,000/ $\mu$ l) and a mild leukocytosis: 19,600/ $\mu$ l (RI 5000–18,900/ $\mu$ l). The results of a biochemical profile were normal except for a mild increase in alanine transaminase activity (ALT) at 113 U/l (RI 6–83 U/l). Coagulation panel showed a normal prothrombin time (PT) of 10.8 s (7.1–11.3 s) and a mildly prolonged activated partial thromboplastin time (APTT) of 34.5 s (18.2–34.0 s). The cat was negative for both feline immunodeficiency virus (FIV) antibody and feline leukaemia virus (FeLV) antigen by enzyme-linked immunosorbent assay (ELISA). Three-view thoracic and abdominal radiographs showed no remarkable findings. Cardiac ultrasonography revealed concentric left ventricular hypertrophy (left ventricular free-wall diastolic thickness: 8.6 mm). There was mitral regurgitation, but systemic systolic blood pressure was not significantly increased (144 mmHg) using a colour Doppler. No abnormalities were found on abdominal ultrasound. A fine-needle aspiration biopsy of the tarsal nodule was

obtained. The smears were air-dried and stained with a rapid modified Romanovsky stain. The smears were moderately cellular and consisted of pleomorphic round cells in a background that contained a large amount of blood. These round cells contained large anisokaryotic, oval nuclei with reticular chromatin and, in some cells, prominent nucleoli, with moderate amounts of pale basophilic cytoplasm. The exact cell of origin was undetermined; however, differential diagnoses included an anaplastic mast cell tumour or histiocytic neoplasm, or, less likely, an anaplastic sarcoma and fibrosarcoma. On day 3, treatment with subcutaneous fluid administration, enrofloxacin (5 mg/kg, SC, q24h), prednisolone (0.5 mg/kg, PO, q24h), and benazepril (0.3 mg/kg, PO, q24h) were started because anorexia had developed. The owner elected to have the left hindlimb amputated by hip joint disarticulation on day 10 because it was felt that

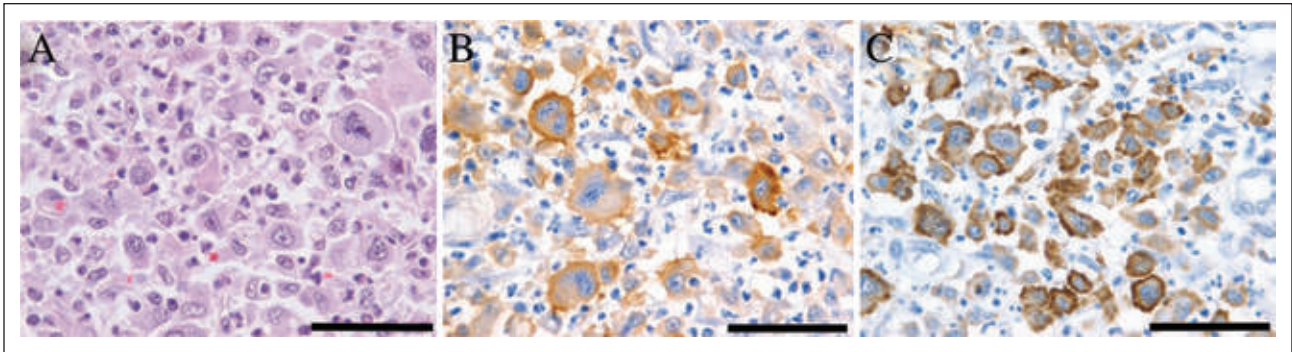
<sup>1</sup>Division of Veterinary Internal Medicine, Department of Veterinary Science, Faculty of Veterinary Medicine, Nippon Veterinary and Life Science University, Tokyo, Japan

<sup>2</sup>Igusa Animal Hospital, Tokyo, Japan

<sup>3</sup>Division of Veterinary Pathology, Department of Veterinary Science, Faculty of Veterinary Medicine, Nippon Veterinary and Life Science University, Japan

## Corresponding author:

Takahiro Teshima DVM, PhD, Division of Veterinary Internal Medicine, Department of Veterinary Science, Faculty of Veterinary Medicine, Nippon Veterinary and Life Science University, 1-7-1 Kyonan-cho, Musashino-shi, Tokyo 180-8602, Japan  
Email: teshima63@nvlu.ac.jp



**Figure 1** Histopathology of the tarsus. The mass is composed of a proliferation of highly pleomorphic cells. Haematoxylin and eosin stain (A). Pleomorphic cells are immunopositive for HLA-DR (B) and Iba1 (C).  $\times 1000$  magnification. Bar = 50  $\mu\text{m}$

it would be difficult to completely excise the mass and there was a risk of recurrence with local resection.

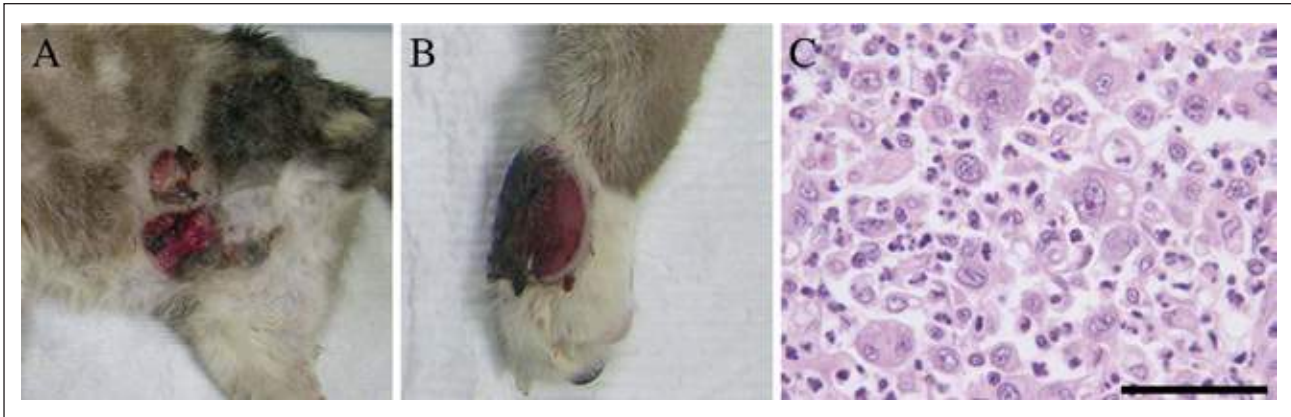On gross examination, the tarsal swelling was firm with cutaneous necrosis and contained a firm, nodular mass of pale colour measuring  $4 \times 3 \times 1.5$  cm. The left popliteal lymph node was also enlarged and was incisionally biopsied. Histological examination revealed neoplastic cells diffusely infiltrating the dermis. The neoplastic cells were oval-to-irregular in shape and varied greatly in size. Nuclei were large, oval-to-irregular in shape and often indented and multiple with coarsely granular chromatin. Nucleoli were large, multiple and darkly stained. Mitotic figures were common and often greater than  $4/40 \times$  field. The popliteal lymph node was diffusely infiltrated by neoplastic cells. The neoplastic cells filled subcapsular and medullary sinuses and they also replaced medullary cords multifocally. The neoplastic cells occasionally contained phagocytosed red blood cells. These neoplastic cells indicated a poorly differentiated malignancy.

Immunohistochemical examination was performed in an attempt to establish the lineage of the neoplastic cells. In dogs, CD1, CD11c, CD18 and canine MHC class II are known as reliable markers for histiocytic sarcoma (HS).<sup>1</sup> In contrast, immunophenotyping has been used to differentiate feline lymphocytes that express CD3 or CD79a and further classification of the histiocytic lineage may be achieved with immunophenotyping for CD1, CD11b, CD11c, CD11d, CD18, CD90, MHC class II and E-cadherin.<sup>2</sup> However, the ideal marker for feline histiocytes is yet to be established. In this case, the neoplastic cells were negative for CD3, B-lymphocyte antigen-36 (BLA36) and lysozyme, but were positive for human lymphocyte antigen-DR (HLA-DR) and ionised calcium binding adaptor molecule 1 (Iba1) (Figure 1). The positive result for HLA-DR indicates these neoplastic cells originated from an antigen-presenting cell, such as dendritic, macrophage or B-cell,<sup>3,4</sup> as Iba1 is specifically expressed in macrophages or microglia.<sup>5,6</sup> The negative result for CD3 and BLA36 indicate cells are not of

T- and B-cell origin. The negative result for lysozyme did not help to further characterise the neoplasm. Lysozyme may be positive with cells of histiocytic origin, but poorly differentiated histiocytes and dendritic antigen-presenting cells may be negative for lysozyme.<sup>7,8</sup> Based on the microscopic appearance and the immunohistochemical characteristics of the neoplasm, a diagnosis of histiocytic sarcoma was made.

After the surgery, the cat's appetite and demeanor improved. Twenty-six days after the surgery, haematology and biochemical analysis showed no abnormalities. However, 44 days after surgery, multiple skin lesions appeared on the back, right femur and left flank. Moreover, 60 days after surgery, new skin lesions also developed on the head, toe of right hindlimb and at the previous site of amputation (Figure 2A and B). Owing to the marked progression of the skin lesions, the owner elected to have the cat euthanased.

In this case, whether there was metastasis to the internal organs was not known as a complete necropsy was not performed. However, post mortem bone marrow aspiration and skin lesion biopsy using Baker's biopsy punch were performed. The bone marrow aspirate was highly cellular, with adequate megakaryocytes. Erythroid and myeloid lines were orderly and well represented, with a mild myeloid hyperplasia (M:E ratio of 2.2). Lymphocytes and plasma cells were within normal range. No neoplastic cells or infectious organisms were identified. The skin biopsy revealed a large focus of ulceration with necrotic debris and an infiltrative neoplasm was present within the underlying tissue. This was composed of oval-to-round or irregularly-shaped cells that varied greatly in size. Nuclei were oval-to-round and often lobulated or multiple, with coarsely granular chromatin. Mitotic figures were numerous and often greater than  $6/40 \times$  field. These neoplastic cells indicated a poorly differentiated malignancy and were similar to that from the left tarsus (Figure 2C). Thus, these skin lesions were diagnosed as a recurrence of histiocytic sarcoma.



**Figure 2** Gross and histological appearance of the skin lesions at recurrence. Gross appearance of the skin lesions at the previous site of amputation (A) and the toe of right hindlimb (B). (C) Pleomorphic histiocytes at the previous site of amputation. Haematoxylin and eosin stain;  $\times 1000$  magnification. Bar = 50  $\mu\text{m}$

Histiocytic proliferative diseases include proliferation of dendritic cells and macrophages and include cutaneous histiocytoma, reactive histiocytosis (cutaneous or systemic form), and malignant histiocytosis (localised and disseminated histiocytic sarcoma) in dogs.<sup>9</sup> Histiocytic sarcoma can occur as a solitary mass with metastases to the draining lymph nodes or as a disseminated form characterised by multi-systemic proliferation of malignant histiocytes. The disease is also uncommon in dogs and has been rarely reported in cats.<sup>2,4,6,10–17</sup> The predilection sites of the primary skin lesions in cats are the feet, legs and head.<sup>2</sup> To the authors' knowledge, this is the first report of a localised histiocytic sarcoma in the extremities treated with amputation in a cat. In a previous report, surgical excision was performed in eight cats with solitary masses or a small number of skin lesions; however, local recurrence occurred in four cats.<sup>2</sup> Moreover, all eight cats developed additional lesions in other locations. Survival, or recurrence-free times, was not described. In contrast, clinical follow-up data are available in dogs with histiocytic sarcoma.<sup>1,18</sup> Wide surgical excisions or amputation with large masses on the extremities were performed in 13 dogs with localised subcutaneous histiocytic sarcoma—no post-surgical recurrence or metastasis was reported in five of the 13 dogs (the remaining eight dogs were lost to further clinical follow-up).<sup>1</sup> In another report, the average time from diagnosis to death or euthanasia was 5.3 months with a range of 0–16 months in 18 dogs with histiocytic sarcoma.<sup>18</sup> In addition, the survival range was 0.5–3 months in five out of 18 dogs treated with amputation alone, whereas in four out of 18 dogs treated with amputation followed with chemotherapy, the survival time was 2–13 months. With regard to chemotherapy for dogs with histiocytic sarcoma, one report showed an overall 50% response rate in 24 dogs with measurable histiocytic sarcoma treated with lomustine, with an overall median survival of 4 months.<sup>19</sup> In cats, protocols used

for treatment of lymphoma may be the best therapeutic approach for this rare tumour.<sup>20</sup> Some cases have received chemotherapy but, to date, no successful treatment has been reported.<sup>16,17</sup> Currently, feline histiocytic sarcoma has a poor prognosis and diagnosis often leads to euthanasia being elected. Further studies are necessary to determine effective treatment for feline histiocytic sarcoma, including, and in addition to, amputation and chemotherapy.

**Funding** This research received no specific grant from any funding agency in the public, commercial, or not-for-profit sectors.

**Conflict of interest** The authors declare that there is no conflict of interest.

## References

- Affolter VK and Moore PF. **Localized and disseminated histiocytic sarcoma of dendritic cell origin in dogs.** *Vet Pathol* 2002; 39: 74–83.
- Affolter VK and Moore PF. **Feline progressive histiocytosis.** *Vet Pathol* 2006; 43: 646–55.
- Imam A, Stathopoulos E, Taylor CR. **BLA.36: a glycoprotein specifically expressed on the surface of Hodgkin's and B cells.** *Anticancer Res* 1990; 10: 1095–104.
- Smoliga J, Schatzberg S, Peters J, et al. **Myelopathy caused by a histiocytic sarcoma in a cat.** *J Small Anim Pract* 2005; 46: 34–8.
- Imai Y, Ibata I, Ito D, et al. **A novel gene *iba1* in the major histocompatibility complex class III region encoding an EF hand protein expressed in a monocytic lineage.** *Biochem Biophys Res Commun* 1996; 224: 855–62.
- Ide T, Uchida K, Tamura S and Nakayama H. **Histiocytic sarcoma in the brain of a cat.** *J Vet Med Sci* 2010; 72: 99–102.
- Moore PF. **Utilization of cytoplasmic lysozyme immunoreactivity as a histiocytic marker in canine histiocytic disorders.** *Vet Pathol* 1986; 23: 757–62.
- Moore PF and Rosin A. **Malignant histiocytosis of Bernese mountain dogs.** *Vet Pathol* 1986; 23: 1–10.

- 9 Fulmer AK and Mauldin GE. **Canine histiocytic neoplasia: an overview.** *Can Vet J* 2007; 48: 1041–50.
- 10 Kraje AC, Patton CS and Edwards DF. **Malignant histiocytosis in 3 cats.** *J Vet Intern Med* 2001; 15: 252–6.
- 11 Walton RM, Brown DE, Burkhard MJ, et al. **Malignant histiocytosis in a domestic cat: cytomorphologic and immunohistochemical features.** *Vet Clin Pathol* 1997; 26: 56–60.
- 12 Bell R, Philbey AW, Martineau H, et al. **Dynamic tracheal collapse associated with disseminated histiocytic sarcoma in a cat.** *J Small Anim Pract* 2006; 47: 461–4.
- 13 Friedrichs KR and Young KM. **Histiocytic sarcoma of macrophage origin in a cat: case report with a literature review of feline histiocytic malignancies and comparison with canine hemophagocytic histiocytic sarcoma.** *Vet Clin Pathol* 2008; 37: 121–8.
- 14 Pinard J, Wagg CR, Girard C, et al. **Histiocytic sarcoma in the tarsus of a cat.** *Vet Pathol* 2006; 43: 1014–7.
- 15 Reed N, Begara-McGorum IM, Else RW and Gunn-Moore DA. **Unusual histiocytic disease in a Somali cat.** *J Feline Med Surg* 2006; 8: 129–34.
- 16 Court EA, Earnest-Koons KA, Barr SC and Gould WJ II. **Malignant histiocytosis in a cat.** *J Am Vet Med Assoc* 1993; 203: 1300–2.
- 17 Freeman L, Stevens J, Loughman C and Tompkins M. Clinical vignette. **Malignant histiocytosis in a cat.** *J Vet Intern Med* 1995; 9: 171–3.
- 18 Craig LE, Julian ME and Ferracone JD. **The diagnosis and prognosis of synovial tumors in dogs: 35 cases.** *Vet Pathol* 2002; 39: 66–73.
- 19 Rassnick KM, Moore AS, Russell DS, et al. **Phase II, open-label trial of single-agent CCNU in dogs with previously untreated histiocytic sarcoma.** *J Vet Intern Med* 2010; 24: 1528–31.
- 20 Ogilvie GK, Moore AS. **Thymoma, mesothelioma, and histiocytosis.** In: GK Ogilvie, AS Moore, ed. *Feline oncology*, 1st edn. Pennsylvania: Veterinary Learning Systems, 2001: 389–97.